

Urolithiasis and Chronic Renal Failure in an Arabian Gelding

Sarah Gold

Advisor and Clinician: Jerome VanBiervliet

Senior Seminar Paper

Cornell University College of Veterinary Medicine

November 5, 2003

## **Abstract**

A 14-year-old Arabian gelding presented to the Cornell University Equine and Farm Animal Hospital Large Animal Medicine Service in August 2003 with a chief complaint of weight loss, polydipsia, polyuria, and dysuria. Upon rectal palpation, a large cystic calculus and bilaterally enlarged ureters were noted. The chemistry panel was consistent with renal failure and urinalysis showed isosthenuria. Further diagnostics included ultrasound of the kidneys, and endoscopy of the urinary bladder. During rectal examinations, the urolith was noted to rest at the trigone region, thereby possibly obstructing the ureters. The horse was stabilized on fluid therapy and a cystotomy was performed to remove the urolith. Post-operatively, renal function was markedly improved, but the horse was ultimately euthanized due to Salmonellosis. Postmortem findings included severe hydronephrosis, hydroureter, and chronic severe cystitis. This case report illustrates the unusual relationship between chronic renal failure and cystic calculi in this horse.

## **Case History**

A 14-year-old arabian gelding was admitted to the Cornell University Equine and Farm Animal Hospital in August 2003 when a referring veterinarian palpated a bladder stone and bloodwork showed signs of kidney disease. In April 2003 the horse was noticed to be polyuric, polydipsic, dribbling urine, and losing weight. A veterinarian examined the horse in May for hematuria, and bloodwork showed a leukocytosis and high BUN. The horse was put on 3-4 week course of Tribissen (trimethoprim-sulfadiazine) for presumptive urinary tract infection; there was no improvement of clinical signs. The horse was examined by another veterinarian in August and referred the horse to Cornell for evaluation of kidney disease and urolith removal.

The horse lived on farm in Pennsylvania with 23 other horses, all of whom were seemingly healthy. He was fed a pelleted complete feed (Bonanza 12% Complete pelleted horse feed: 12.5% crude protein, 3.5% crude fat, 1.7% Ca, 0.49% P) along with a textured feed (Legend 10 Textured 6% fat horse feed: 10% CP, 6% CF, 0.75%-1.25% Ca, 0.50% P) for the past 10 years. His hay was timothy mixed with birds foot and tree foil that was cut on the farm's property. He was put on pasture (similar to hay composition) as well when noted to be losing weight, and was also given beet pulp in addition to his regular feed. None of the dietary elements were noted to be of excessive calcium or other mineral content; there was also no history of alfalfa in the horse's diet.

### **Physical Examination and Preliminary Diagnostics**

The horse was noted to be extremely thin, with a body condition score 1/5. There were multiple crusting alopecic areas along dorsum and limbs which were identified as severe dermatophilosis (rain rot). Vital signs were within normal limits, and severe dental tartar was noted. The horse would stand with his penis partially dropped and dribble urine, and he exhibited dysuria. A rectal examination was performed, and a "baseball-sized" calculus was found in the apex of the urinary bladder and bilaterally enlarged turgid ureters were noted. These findings were confirmed with transcolonic ultrasound, and the bladder wall appeared thickened. There were no calculi apparent in the ureters or kidney.

The complete blood count showed a profound leukocytosis and neutrophilia, indicating infection. There was also a lymphopenia present, which could be a component of stress, and stress could be a minor component of the neutrophilia. Renal failure was indicated in the blood chemistry panel, as renal disease without failure rarely causes abnormalities in serum

chemistries<sup>1</sup>, and the following abnormalities were noted: hyponatremia, hyperkalemia, hypochloremia, hypercalcemia, hyperproteinemia, azotemia, and elevated fibrinogen.

Hyponatremia, hypochloremia, and hyperkalemia are present in most cases of renal failure as the kidney loses its ability to regulate these electrolytes. Hypercalcemia is associated with the unique role of the equine kidney in calcium regulation. Horses excrete a large amount of Ca in urine when serum levels are increased, and hence calcium accumulates in equine chronic renal failure. Phosphate usually varies inversely with potassium with renal disease. Hyperproteinemia indicates chronic inflammation, dehydration, and/or infection, and increased fibrinogen further indicates inflammation. Free catch urine was submitted for urinalysis, and isosthenuria, pyuria, red blood cells, hemoproteins, and gram positive cocci were seen (no casts or crystals were noted). Urinalysis and serum creatinine determination are the most valuable lab tests for detecting renal dysfunction and disease, and both isosthenuria and azotemia were present<sup>2</sup>.

Hence, a diagnosis of renal failure was made. Acute renal failure is seen with drug toxicities, vitamin D toxicity, mercury poisoning, and infectious causes such as Actinobacillosis or Leptospirosis. But these horses present with hypovolemia and shock. Chronic renal failure has a more insidious onset, as there is a slow progressive loss of nephron population and function. There needs to be a 60-70% loss of renal parenchyma to see signs of kidney failure, and these horses present with weight loss, polyuria, polydipsia, and dental tartar<sup>1</sup>.

Chronic renal failure can be attributed to 2 disease processes, those affecting the glomerulus, and those causing tubulointerstitial disease. Tubulointerstitial disease can be caused by many factors. First, there can be chronic or intermittent obstruction which is usually found in the ureters or renal pelvis, and abdominal pain can be present if calculi are present in the ureters. Pyelonephritis is chronic septic condition of the kidneys due to ascending infection, but this is

more common in mares, given their anatomy. Affected horses would present with hematuria and pyuria. Another cause of chronic renal failure is renal papillary necrosis due to nonsteroidal anti-inflammatory drug toxicity (rarely), aminoglycoside toxicity, excessive pigment deposition (such as is seen in red maple toxicity), septic/ischemic processes, and nephrolithiasis, and these lead to a chronic interstitial nephritis. Finally, any abnormalities interfering with normal urine flow, such as neoplasia, renal dysplasia, trauma, calculi, or neurologic disease can allow bacterial colonization and lead to subsequent renal failure<sup>1,2</sup>.

Chronic glomerular diseases are usually immunologic in nature, and affected horses have proteinuria, and hypoproteinemia, leading to pitting edema. Immune-mediated glomerulonephritis is the most common cause of glomerular disease, where antibody-antigen complex deposition on glomeruli occurs (such as in streptococcus infections and equine infectious anemia). Other causes include renal hypoplasia, amyloidosis, and glomerulosclerosis<sup>1,2</sup>.

The other major clinical finding was the presence of a large bladder stone. The prevalence of equine urolithiasis is low, comprising 0.04% to 0.5% of equine diagnoses<sup>3</sup>. Uroliths are most commonly found in adult geldings due to differences between urethra length, width, and distensibility when compared to mares<sup>4</sup>. Exact method of urolith formation is unclear. Either abnormally high urine concentrations of insoluble complexes are present, or there are inappropriately low amounts of complex inhibitors in the urine<sup>5</sup>. Normal equine urine is heavily laden with calcium carbonate crystals and mucoproteins. Formation of uroliths is further favored by the alkaline pH of equine urine, and the presence of mucinous clots and desquamated cells may serve as a nidus around which a urolith may form<sup>3</sup>. A nidus can also be provided by an infection or renal papillary or tubular necrosis<sup>6</sup>. In adult horses, nidus formation due to prior

renal insult is most common and pyelonephritis is rare<sup>1</sup>. It is to be noted that this particular horse did not have a history of NSAID administration. Urolith formation has not been demonstrated to be associated with dietary levels of minerals or carbohydrate content, contrary to what is reported in affected ruminants. Studies in humans have shown that people affected by urinary tract calculi may be deficient in urine protein inhibitors, which inhibit crystallization of salts in the urine, and this could be similar in individual horses<sup>5</sup>.

Therefore, two different possibilities existed to explain the disease processes occurring in this particular horse. Either the obstructive calculus played a significant role in the progression of renal disease to end stage renal failure, or the urolith occurred secondary to urinary tract disease. A urinary tract infection could pull the clinical picture together nicely, serving to provide a nidus for urolith formation and inciting renal disease, and it would also explain the horse's high white cell count, but no bacteria were cultured from his urine. Furthermore, it was necessary to determine the extent of renal disease, as treatment is not warranted in animals with chronic renal failure with evidence of significant bilateral renal fibrosis, indicating irreversible damage<sup>5,6</sup>. Further diagnostics were obligatory, as horses affected with bladder stones usually present as systemically healthy but with signs of urinary obstruction, colic, or hematuria following exercise. This horse's presentation was not typical. It was also necessary to see if the horse could be stabilized for cystotomy to remove the bladder stone which was obviously causing discomfort and dysuria. Additional ureteroliths or nephroliths needed to be identified, as their presence would indicate more extensive treatment was necessary. Thoracic radiographs were taken to rule out neoplastic processes, pneumonia, and other causes of weight loss/infection, and these were normal. The horse was placed on fluid therapy overnight, and further tests were performed the following day.

## **Ancillary Diagnostics**

Determining the size, shape, position, and echogenic texture of the kidneys could allow for a more accurate assessment of renal function, and this has been greatly facilitated by abdominal ultrasound. Dilations of the recesses and pelvis are readily determined, and characteristic acoustic shadowing identifies mineral densities (calculi)<sup>7</sup>. Abdominal ultrasound was performed, and bilateral pyelectasia and bilateral ureterectasia were noted. Both kidneys had normal shape, echogenicity, corticomedullary structure, and size. No calculi were detected in the ureters or kidneys. Endoscopy of the urethra and bladder was performed to search for structural abnormalities and assess damage. The mucosa of bladder and urethra appeared reddened and inflamed in several areas. Ureters were seen entering the bladder at appropriate positions and were patent, ruling out abnormal anatomy as a predisposing cause for urine stasis, bacterial infection, and nidus formation. The urolith was also seen resting at the apex of the bladder, where it was not interfering with ureteral emptying, and was noted to be yellow and spiculated (this was presumably a calcium carbonate stone, given its appearance)<sup>8</sup>. Subsequent rectal palpations showed that the urolith would intermittently sit at the trigone region, and prevent normal urine flow from the bladder (as the horse would urinate if the urolith was pushed into the apex region), and this positioning could presumably also intermittently block the ureters. It was concluded that the urolith could be the primary cause of renal failure (obstructive), and that both kidneys appeared to have some functional reserve, as azotemia and electrolyte abnormalities improved with supportive care. A glomerular filtration rate (GFR) study could quantitate the functional capacity of the kidneys, but it was decided to postpone testing until after the bladder stone was removed as the presence of the urolith could interfere with test results<sup>6</sup>. A

multi-drug resistant *E. Coli* was finally cultured from urine that was susceptible to Naxcel, so antibiotic therapy was initiated. Cystotomy was scheduled for the following day to remove the stone.

### **Treatment**

The horse was placed off-feed 8 PM the night before surgery to decrease gut fill to ease the act of locating bladder during surgery. He was bright, alert and responsive the morning of surgery, and vital parameters were within normal limits. The horse was placed in dorsal recumbency, prepped and draped in standard aseptic technique, and a urinary catheter was positioned to keep the bladder drained. A 13 cm left parainguinal incision was made using a #20 scalpel blade and subcutaneous tissues were bluntly dissected. The incision was retracted to midline with Richardson retractors along with the pudendal vessels and nerves. An incision was made in the area of the external abdominal ring through the fascia of the external abdominal oblique and rectus abdominus muscle. The peritoneum was entered bluntly, and the bladder was identified and exteriorized. It was approximately 10 cm in diameter and the wall was thickened and collapsed around the urolith. A wet lap sponge was used to keep the bladder exteriorized by twisting it about the neck and stay sutures were placed. Using a #10 blade, an 8 cm incision was made through the wall of the bladder and the urolith was removed. The urolith was 4 x 6 x 8 cm and weighed 237 grams. The bladder mucosa was inspected and noted to look inflamed. The bladder was lavaged with saline and sutured closed in 2 layers using a Lembert pattern with 2-0 vicryl (usually used to close hollow viscous). The bladder was replaced back into the abdominal cavity. The rectus abdominus muscle was closed with a simple continuous pattern with 2-0 vicryl, the external sheath of the external abdominal oblique (holding layer) was closed

with 2 vicryl, the subcutaneous tissues were closed with 2-0 vicryl, and a simple continuous pattern was used to close skin with 0 monocryl. The catheter was removed, and the horse recovered from anesthesia without complications.

### **Outcome**

The horse did very well after surgery. He urinated normally with normal posture shortly after recovery, and produced urine in a steady flow. He passed normal manure, had a ravenous appetite, and rested comfortably with a normal heart rate. Further analysis of the stone indicated that it was composed of 95% calcium carbonate and 5% calcium oxalate dihydrate. This is the most common type of urolith found in horses, and they appear to form as a concretion of urinary salts<sup>8</sup>.

Figure 1 shows the horse's fluid intake during his stay at Cornell. Normal intake for a horse this size is indicated at 35 L per day. He was polydipsic when he presented and intravenous crystalloid fluid therapy was initiated to diurese his kidneys. The crystalloids were discontinued post-operatively, and it is evident that the horse's polydipsia began to abate, and he maintained an adequate water intake on his own. Even with a lower fluid intake, the horse's creatinine was resolving well (Figure 2). Normal high creatinine for Cornell's diagnostic laboratory is indicated at 1.8 mg/dL, and this horse's was reduced to 2.1 mg/dL. It is believed that horses with chronic low grade azotemia with a creatinine of up to 3.0 mg/dL, can still be useful for light riding and breeding, and this horse was in retirement<sup>9</sup>. His BUN followed a similar trend.

A GFR study to determine the extent of his residual kidney function was scheduled to be performed in the next few days, and the horse was scheduled to be sent home later the following week if he continued to do well. Unfortunately, the horse developed a severe case of

Salmonellosis, and fecal culture was positive for Salmonella Type B, likely to be *S. typhimurium* DT104. He was euthanized following evidence of disseminated intravascular coagulation, endotoxic shock, and multiple organ failure.

A necropsy was performed the following day, and moderate autolysis was noted. There was ventral edema, and edema within prepuce and hindlimbs as well. Within the musculature of the proximal hind limbs, the edema was manifested as yellow gelatinous fluid. Protein loss from GI tract or vasculitis secondary to endotoxemia and DIC could facilitate this severe ascites. The abdomen contained approximately 10 L of clear yellow fluid, attributed to ascites. The heart had shiny gelatinous material within coronary, paraconal, and subsinusal grooves. This was interpreted as chronic moderate serous atrophy of fat due to negative energy balance secondary to chronic renal failure.

The right and left kidneys were diffusely plump and turgid, bulged on cut surface, and contained markedly dilated renal pelvises; this was interpreted as chronic severe hydronephrosis, due to chronic urolith obstruction. Histology of the kidney cortices revealed mild dilation of distal convoluted tubules and they contained proteinaceous exudate. There was also necrosis of tubules, but basement membranes were intact and surviving epithelial cells flattened out to try to maintain barrier integrity. Medullary components were seen pushed into the proximal cortex and were moderately atrophied due to hydronephrosis. The medullary ducts were mildly dilated, and there was a mildly increased amount of collective tissue (collagen) in all areas of the renal parenchyma demonstrated with trichrome staining. The morphologic diagnosis was severe diffuse subacute to chronic medullary atrophy (hydronephrosis).

The right and left ureters were markedly dilated to approximately 3 times normal diameter. This lead to a postmortem diagnosis of chronic severe hydroureter due to chronic

urolith obstruction. Transitional epithelium is denuded, and fibrous tissue was present in the smooth muscle layer, which was grossly hypertrophied. The bladder wall was diffusely thickened (chronic severe cystitis), and the mucosal surface at neck of bladder contained a 1 x 1 cm ecchymosis due to chronic irritation by the spikes of the urolith. Similar to the ureters, the transitional epithelial layer is denuded (mucosal loss), and there was fibrosis and smooth muscle hypertrophy on histologic examination.

It was the opinion of the Cornell University Pathology Department that while this horse had some evidence of irreversible change in the renal parenchyma, the horse most certainly could have lived with these kidneys with some mild concentrating deficits.

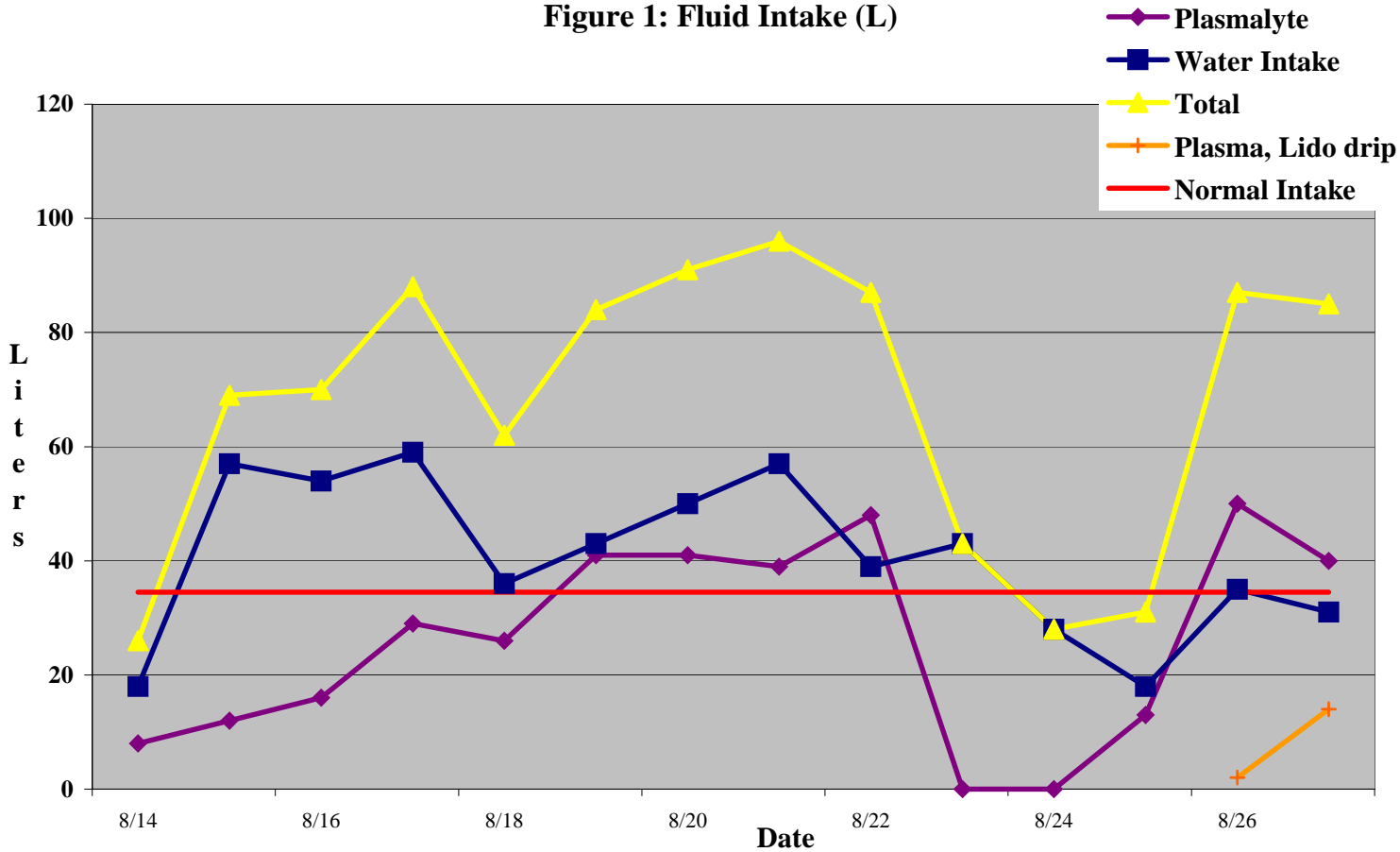
## **Conclusion**

Cystic calculi are rare cause of chronic renal failure in the horse; indeed the majority of the literature focuses on stones in the kidney or ureter as causes for obstruction and consequent renal failure. The factors leading up to the formation of urolithiasis in the horse are poorly understood, but clinical presentation is clearly reported. The clinical signs of urolithiasis usually include moderate to severe abdominal pain due to urethral obstruction, and if the calculus is non-obstructive, the horse will typically present for evaluation of pollakiuria, dysuria, stranguria, and hematuria. Hence, this horse which presented with renal failure may be the consequence of urolithiasis of too prolonged a duration (rare case of obstruction). The inciting cause for urolith formation was not identified. Similarly, if renal disease provided the nidus for urolith formation, no distinguishing cause was ascertained. The *E. coli* identified on urine culture could be evidence of a urinary tract infection (providing a nidus and/or inciting renal disease), or colonization could have occurred once the urinary tract was compromised due to the presence of

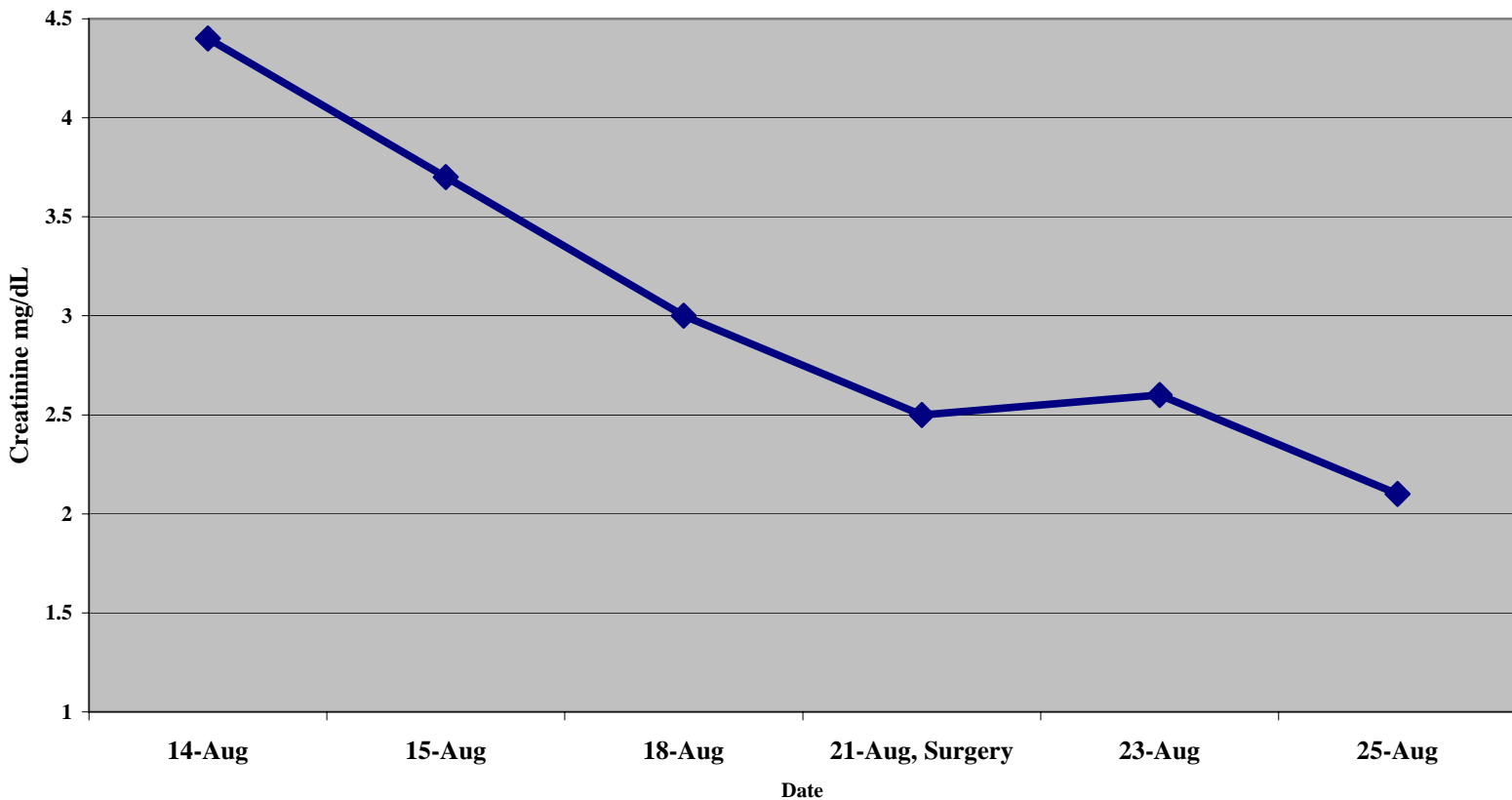
the urolith.

In horses with extensive renal, treatment may not be warranted due to the poor prognosis. However, the kidneys have an enormous residual capacity, and regardless of the duration of time that the urolith was present, urolithiasis is a surgical disease. If urolithiasis is promptly identified, a variety of surgical techniques (cystotomy and perineal urethrotomy are recommended) can be applied to treat this condition, and horses can do very well. Finally, if calcium carbonate is identified in nearly every equine urolith and equine urine is weighted with calcium salts, it is curious that the prevalence of equine urolithiasis is so low. This indicates that the pathogenesis of urolith formation in affected horses needs to be further explored; then possible preventative steps can be taken in affected individuals.

**Figure 1: Fluid Intake (L)**



**Figure 2: Serum Creatinine (mg/dL)**



## **References**

1. Divers TJ. Urinary system. In: Reed SM, Bayly WM, eds. *Equine Medicine and Surgery*. Philadelphia, WB Saunders; 1998 1760-1780.
2. Schott HC, VanMetre DC, Divers TJ. Diseases of the renal system. In: Smith BP. *Large Animal Internal Medicine*. Philadelphia: Mosby, Inc, 2002; 824-843.
3. Laverty S, Pascoe JR, Ling GV, et al. Urolithiasis in 68 horses. *Vet Surgery* 1992; 21: 56-62.
4. Wooldridge AA, Seahorn TL, Williams J, et al. Chronic renal failure associated with nephrolithiasis, ureterolithiasis, and renal dysplasia in a 2-year-old quarter horse gelding. *Vet Radiol Ultrasound* 1999; 40: 361-4.
5. Divers TJ. Nephrolithiasis and ureterolithiasis in horses and their association with renal disease and failure. *Equine vet J* 1989; 21: 161-2.
6. Ehnen SJ, Divers TJ, Gillette D, Reef VB. Obstructive nephrolithiasis and ureterolithiasis associated with chronic renal failure in horses: eight cases [1981-1987]. *J Am Vet Med Assoc* 1990; 197: 249-253.
7. Rantanen NW. Diseases of the kidneys. *Vet Clin North Am Equine Pract* Apr 1986; 2: 89-103.
8. DeBowes RM. Surgical management of urolithiasis. *Vet Clin North Am Equine Pract* Dec 1988; 4: 461-471.
9. Van Biervleit J, Divers TJ, Porter B, et al. Glomerulonephritis in horses. *Comp Cont Ed* 2002 24: 892-902.